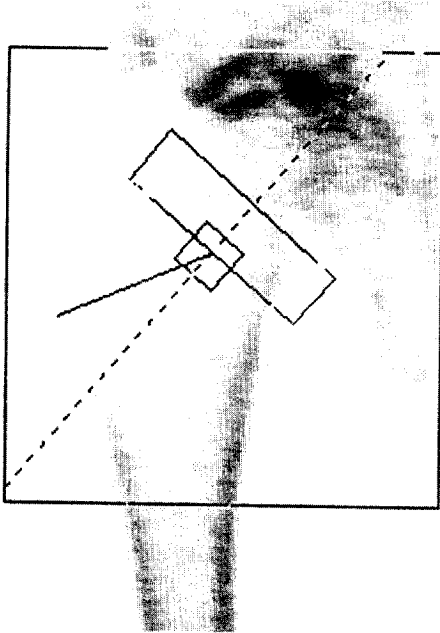


Name: CHYUMAKOVA, I K
 Patient ID: CIK-AMB
 DOB: 08 February 1961

Sex: Female
 Ethnicity: White

Height:
 Weight:
 Age: 51

Referring Physician:



k = 1.148, d0 = 45.8
 96 x 100
 NECK: 49 x 15

Scan Information:

Scan Type: f Right Hip
 Analysis: 11 January 2013 11:55 Version 12.6:3
 Right Hip

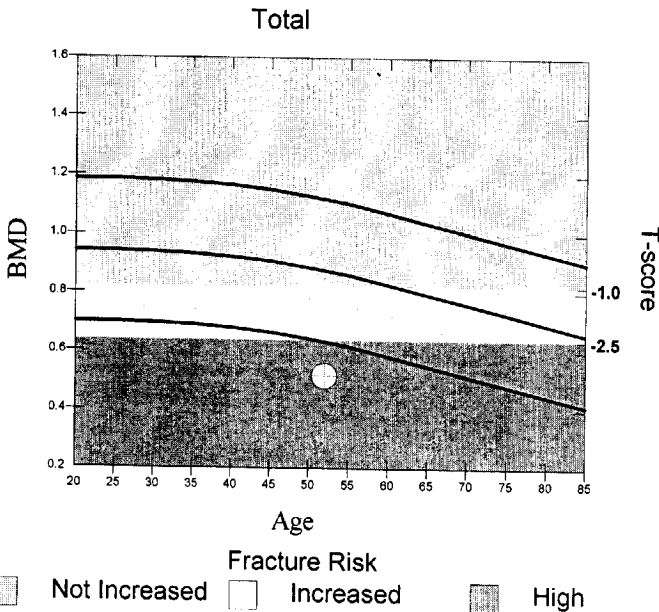
Operator:
 Model: Discovery A (S/N 82263)
 Comment:

DXA Results Summary:

Region	Area (cm ²)	BMC (g)	BMD (g/cm ²)	T-score	Z-score
Neck	4.89	2.74	0.560	-2.6	-1.7
Total	32.35	16.67	0.515	-3.5	-3.0

Total BMD CV 1.0%, ACF = 1.044, BCF = 1.009, TH = 7.011

WHO Classification: Osteoporosis
 Fracture Risk: High



T-score vs. White Female; Z-score vs. White Female. Source: NHANES

Physician's Comment:

*Достоверно в шейке
 правого бедра T = -2.6
 и вертлбе T = -3.5
 в левом бедре HOLOG
 (Troch) T = -4.0,
 мембедренная шн (Intera) T = -3.3*

11.01.13